

This article is a preprint. It has been reviewed, accepted for publication, and approved by the author but has not been copyedited, proofread, or typeset.

ORIGINAL ARTICLE

Partial Ankle Arthroplasty: Talus Resurfacing for Mild to Moderate Osteoarthritis and Talus Hemiarthroplasty for Complex Osteochondral Lesions

Nik Žlak, MD, PhD*

Matic Kolar, MD*

Nedim Mujanović, MD†

Matej Drobnič, MD, PhD*

*Department of Orthopedic Surgery, University Medical Centre Ljubljana and Chair of Orthopedics, Faculty of Medicine, University of Ljubljana, Slovenia.

†Department of Orthopedic and Trauma Surgery, University Medical Centre, Sarajevo, Bosnia and Herzegovina.

Corresponding author: Nik Žlak, MD, PhD, Department of Orthopedic Surgery, University Medical Centre Ljubljana, Zaloška ulica 9, SI-1000 Ljubljana, Slovenia, EU. (E-mail:

nik.zlak@kclj.si)

Background: To present prospective short-term results of a limited patient series treated with two innovative partial ankle arthroplasties: talar dome resurfacing for mild-to-moderate ankle osteoarthritis (OA) and talar shoulder hemiarthroplasty for chronic medial osteochondral lesions of the talus (OLT).

This article is a preprint. It has been reviewed, accepted for publication, and approved by the author but has not been copyedited, proofread, or typeset.

Methods: Eleven subjects underwent talus resurfacing, and six subjects were enrolled for talar hemiarthroplasty. The outcome was followed by patient-reported measures and by pursuing serious adverse events or implant failures over a 2-year period. Progression of ankle osteoarthritis, peri-implant bone changes, and implant migration were followed radiographically.

Results: Active dorsiflexion increased from 3° to 10° in resurfacing and from 15° to 22° in hemiarthroplasty. Patient-reported ankle function, quality of life, and activity level tended to improve only slightly after resurfacing (FAOS cumulative = 41 to 42; FAAM-ADL = 43 to 46; EQ-5D 3L = 0.38 to 0.39, Tegner activity scale = 1.6 to 2.0), but moderately after hemiarthroplasty (FAOS cumulative = 58 to 68, FAAM-ADL = 37 to 71, EQ-5D 3L = 0.53 to 0.72, Tegner activity scale = 3.1 to 3.1). No implant-related radiographic changes, implant failures, or implant-related revision surgeries were recorded.

Conclusions: Based on a small and heterogeneous prospective case series, both partial ankle implants investigated were safe and stable over a 2-year follow-up period, without any radiographic OA progression of the remaining joint. However, patient-reported ankle function, quality of life, and activity level showed a tendency of only minor improvement after resurfacing but a moderate increase after hemiarthroplasty.

Partial ankle arthroplasty is an innovative treatment option for two common ankle conditions: moderate osteoarthritis (OA) and chronic osteochondral lesions of the talus (OLTs), which both

This article is a preprint. It has been reviewed, accepted for publication, and approved by the author but has not been copyedited, proofread, or typeset.

cause substantial patient disability [1]. Conservative management is the first-line treatment for symptomatic mild-to-moderate ankle OA. However, when it fails, joint-preserving surgical interventions, such as ankle debridement, supra-/infra-malleolar osteotomy, or distraction chondroplasty may be employed [2]. Talar dome resurfacing (Ankle Spacer[®], Arthrex GmbH, Germany) was recently introduced to help patients in whom these surgical interventions are not indicated or have already failed. The implant is indicated for ankles with mild-to-moderate symmetrical wear of the articular cartilage and good bone stock. Concomitant ankle stabilization procedures are allowed. The implant comes in six sizes to cover most of the talar dome; the malleolar joint spaces remain intact. It is fixed to the talus with a trabecular rough metal surface and two anterior pegs, and its smooth superior surface articulates against the remaining articular cartilage of the tibial plafond. The resurfacing implant may be freely combined with other ankle procedures, such as ligament repair or osteotomies. Because this device was only registered and introduced into clinical practice in 2016, no mid- to long-term outcome reports have yet been published. There is only one publication presenting the surgical technique and short-term 3-month results [3]. OLTs are joint-surface lesions affecting both parts of the osteochondral unit—the cartilage and its underlying subchondral bone—that may cause debilitating symptoms and, if left untreated, present a risk factor for the development of secondary osteoarthritis [4, 5]. Arthroscopic lesion debridement and bone marrow stimulation is the most common therapeutic modality for uncomplicated lesions [6]. Complex cases, such as deep lesions, cystic lesions, and revision surgeries, often require open surgical intervention via

This article is a preprint. It has been reviewed, accepted for publication, and approved by the author but has not been copyedited, proofread, or typeset.

medial malleolar osteotomy [7]. In such cases, osteochondral autografts, allografts, osteochondral scaffolds, or hemiarthroplasty metal implants may be utilized [8]. Talus HemiCAP® (Arthrosurface Inc., USA) was specifically designed for the treatment of chronic, large, deep, or recurrent OLTs on the medial talus shoulder with weak biological potential. The implant is introduced through a medial malleolar osteotomy. It comes in only one surface size (15 mm), but it is slightly angulated (with 15 different angle options) to fit the superior and medial talus surface over OLTs. HemiCAP® is stabilized into the bone with a central screw; it must be positioned slightly below the surrounding articular surfaces to avoid protrusion when the native cartilage is compressed [9, 10]. This implant was introduced in 2007, and positive outcomes have been demonstrated in limited patient series over short-term and even mid-term follow-up [11–13]. This study presents the 2-year results of a limited patient series treated with partial ankle implants for mild to moderate OA or chronic medial OLTs.

Materials and Methods

Study Design

The study presents a prospective case series of two partial ankle arthroplasty implants. The clinical investigational plan was approved by the National Medical Ethics Committee (permit no. 0120-99/2019/4). Adult subjects operated on between January 2018 and June 2019 were enrolled in this study. The inclusion criteria for talus resurfacing were symptomatic mild to moderate primary or secondary ankle OA (Kellgren–Lawrence grades 2–3) with symmetrical

This article is a preprint. It has been reviewed, accepted for publication, and approved by the author but has not been copyedited, proofread, or typeset.

cartilage wear and preserved talar bone stock. The inclusion criteria for talus hemiarthroplasty were chronic complex medial OLTs (Hepple grades 4–5) [14, 15]. Necessary concomitant procedures around the ankle were allowed in both groups.

Subjects

Eleven subjects—seven females and four males, mean age 54 ($SD = 14$) years, mean BMI 27.4 ($SD = 5.6$) kg/m^2 with mild to moderate OA—were enrolled for talus resurfacing. The etiology of their ankle OA was posttraumatic (seven cases), post-OLT (two cases), psoriatic arthritis (one case), and hemophilic arthropathy (one case). Two of them had undergone a previous attempt at talar cartilage repair, and another two had undergone arthroscopic debridement. Six subjects were enrolled for talar hemiarthroplasty: two females and four males, mean age 54 ($SD = 7$) years, mean BMI 30.2 ($SD = 3.5$) kg/m^2 . All of them presented with a symptomatic chronic OLT on the medial talus with cystic subchondral bone involvement, all Hepple grade 5. One subject had undergone a previous OLT repair with an osteochondral scaffold. Details on the subject demographics, medical history, and surgical procedures are presented in Table 1.

Surgical Intervention

All subjects were operated on by the senior coauthor of this article (MD). Talus resurfacing with Ankle Spacer[®] was conducted through an anterior ankle arthrotomy following the prescribed surgical technique with dedicated instruments and intraoperative radiographic control [4]. Two

This article is a preprint. It has been reviewed, accepted for publication, and approved by the author but has not been copyedited, proofread, or typeset.

subjects required radical removal of extensive anterior osteophytes, three subjects received additional Achilles or gastrocnemius lengthening, and a supra- or infra-malleolar osteotomy was conducted in two subjects. A medial malleolar osteotomy exposure was used for talus hemiarthroplasty with HemiCAP[®]. Again, the recommended surgical technique, dedicated instruments, and intraoperative radiographic control were used for implant positioning [9]. The malleolar osteotomy was re-fixated with three cannulated screws. One hemiarthroplasty subject received a concomitant subtalar fusion, and a flexible flatfoot was corrected with an arthroereisis device in another case. See Table 1 for subject and surgery details.

Rehabilitation

Postoperatively, all the subjects avoided weight bearing for 2 months by using crutches (4 weeks total unloading of the operated limb, and another 4 weeks of weight bearing as tolerated). In addition, removable posterior short-leg plastic splint immobilization was used, and only a passive range of motion exercise was allowed until the wounds were fully healed, in about 3 weeks. From that time onward, the subjects were allowed active and passive dorsal/plantar exercises without side motion. Stationary cycling was allowed after 1 month. At 2 months, they discontinued using crutches, and they progressed to proprioceptive exercise, aquatic rehabilitation, and gait training. After 3 months they were allowed strength training, including elliptical trainers, and Nordic walking on stable ground. Six months after surgery they

This article is a preprint. It has been reviewed, accepted for publication, and approved by the author but has not been copyedited, proofread, or typeset.

were allowed all activities in accordance with their ankle's functional status and general health condition.

Clinical And Radiologic Evaluation

The subjects' demographics (age, sex, and BMI), medical history (general health status, ankle OA etiology, and previous interventions), and employment status were recorded during the screening visit. Preoperative weight-bearing AP and lateral radiographs, and computed tomography or magnetic resonance images were analyzed for the OA stage (Kellgren–Lawrence classification) [14] and OLT grade [15]. Subjects were clinically evaluated preoperatively, and then at 6, 12, and 24 months postoperatively. First the range of active dorsi- and plantar-flexion was measured with a goniometer. Routine ankle-specific and general quality-of-life outcome measures were used: the Foot and Ankle Outcome Score (FAOS) [16], European quality of life in five dimensions three-level time-trade off (EQ-5D 3L TTO) [17], Foot and Ankle Ability Measures (FAAM) for daily activities (FAAM-ADL) [18], and Tegner activity scale [19]. Serious adverse events (defined as any hospitalization or revision surgery) or implant failures were pursued. The weight-bearing ankle radiographs were repeated at all evaluation timepoints: Kellgren–Lawrence grading for OA and peri-implant bone changes or implant migration were analyzed. Only the preoperative and the final postoperative values at 2 years are presented.

Statistical Analysis

This article is a preprint. It has been reviewed, accepted for publication, and approved by the author but has not been copyedited, proofread, or typeset.

Descriptive statistics were used for subjects' demographics, medical history, and operative details. Continuous variables are presented as means with standard deviation (*SD*). A paired *t*-test was used to compare preoperative and final postoperative differences in patient-reported outcome measures. Statistical analysis was performed using the statistical software IBM SPSS® Statistics V23.0 (IBM Corp, Armonk, NY, USA). The level of statistical significance was set at $p < .05$.

Results

No implant removals were performed within the observed timeframe. Two subjects from the resurfacing group (one arthroscopic synovectomy with biopsy, one posterior ankle osteophyte removal), and one subject from the hemiarthroplasty group (re-arthrodesis of subtalar non-union) required surgical re-intervention; this was not considered implant-related. The range of active dorsiflexion increased significantly in both groups; from 3° (*SD* = 4°) to 10° (*SD* = 9°) in the resurfacing group ($p = 0.034$) and from 15° (*SD* = 6°) to 22° (*SD* = 4°) in the hemiarthroplasty subjects ($p = 0.025$). In contrast, a non-significant decrease in active plantarflexion was established after resurfacing, but there was a tendency toward an increase after hemiarthroplasty. None of the FAOS subscales revealed significant changes in comparison to the preoperative levels, but there was a general trend of minor improvement after resurfacing and moderate improvement after hemiarthroplasty. Based on the FAOS pain subscale, 5/11 of the talus resurfacing subjects and 4/6 of the hemiarthroplasty subjects reported clinically

This article is a preprint. It has been reviewed, accepted for publication, and approved by the author but has not been copyedited, proofread, or typeset.

meaningful improvement. The patients' quality of life improved minimally after resurfacing and moderately after hemiarthroplasty; however, both changes were non-significant. There was significant improvement in FAAM-ADL from 37 ($SD = 15$) to 71 ($SD = 26$, $p = 0.004$) after hemiarthroplasty, whereas it remained practically the same in the talus resurfacing group. Patients' reported activity levels on the Tegner scale showed mild, non-significant improvement after talus resurfacing but no changes after hemiarthroplasty. Kellgren–Lawrence ankle radiographic scores remained constant in both groups over a 2-year period. At the preoperative screening, eight subjects were employed and three were retired in the resurfacing group, compared to five subjects employed and one retired in the hemiarthroplasty group. All of the working subjects from both groups maintained their working status postoperatively. However, two subjects from the talus resurfacing group and another two subjects from the hemiarthroplasty group required work modification at the final follow-up evaluation. No peri-implant osteolysis or implant migration was noted at the 2-year postoperative radiographs. Details on the clinical and radiographic outcomes are presented in Table 2. The preoperative and 2-year postoperative radiographs of two representative cases are shown in Figure 1.

Discussion

The main findings of this case series were that the implantation of both partial ankle implants was a safe procedure and that the implants were stable over a period of 2 postoperative years without any radiographic criteria for OA progression (additional osteophyte formation, joint

This article is a preprint. It has been reviewed, accepted for publication, and approved by the author but has not been copyedited, proofread, or typeset.

narrowing, or subchondral bone irregularities) of the remaining ankle joint. Both operative procedures also improved the range of ankle motion toward dorsiflexion. Although the increment of patients' perceived ankle function, quality of life, and activity level was not significant in general, a tendency toward minor improvement of these parameters was observed in the resurfacing subjects, whereas the improvement after hemiarthroplasty may be considered moderate.

First, it needs to be highlighted that the two different partial ankle implants do not share the same treatment indication: mild to moderate OA versus complex OLT. Nevertheless, the two implants share certain features: they are both implanted onto the talar dome, and they articulate against native articular cartilage of the distal tibia. In relation to the surgical indication, OLT is a predominately focal cartilage-bone disorder, whereas OA involves all the structures of the diseased joint. Accordingly, radiographically graded ankle OA was significantly higher in subjects that had received talus resurfacing. Ankle-related functional impairment was therefore expectably higher in OA subjects—however, not to a statistically significant extent. A similar conclusion was established in another study, which pointed out that subjects with advanced ankle OA and ones with recurrent OLT presented similar preoperative symptoms and ankle dysfunction [20].

Both implants were considered stable, without any peri-implant bone loss according to the 2-year radiographic evaluation. Radiographically, we also could not detect any subchondral bone anomalies on the opposing tibial surface. From the biomechanical standpoint, talus

This article is a preprint. It has been reviewed, accepted for publication, and approved by the author but has not been copyedited, proofread, or typeset.

resurfacing was positioned directly onto the subchondral bone, whereas hemiarthroplasty was positioned slightly below the surrounding articular surface. A similar concept of recessed implants is also followed in biological OLT repair when rigid osteochondral repair devices are used [21]. Referring to the concept of patellofemoral knee arthroplasty, talus resurfacing would be considered an onlay, whereas hemiarthroplasty works as an inlay. The later concept is currently favored in the patella–femoral area [22]. In any case, resurfacing of the complete talar dome cannot be performed because an inlay concept as the implant needs to fill the gap of missing cartilage tissue. The concept of resurfacing the entire convex articular surface, which freely articulates against the native concave articular surface, has been successfully implanted for decades in partial hip and shoulder arthroplasties. In our resurfacing cases, in contrast, clinically meaningful improvement was confirmed in only half of the subjects operated on. This may be attributable to the indication differences between Ankle Spacer® (mild to moderate OA) and standard shoulder or hip partial arthroplasty (fracture or necrosis of the femoral or humeral neck/head with mostly preserved cartilage on the acetabulum or glenoid) [23, 24]. Even under such circumstances, up to 10% of partial hip and shoulder arthroplasties are converted to total replacement due to pain without any mechanical implant loosening [25, 26]. Certain residual ankle pain in the setting of mild to moderate OA in our subjects, in whom the opposing cartilage or subchondral bone was also already diseased, therefore cannot be avoided. Based on the 2-year results presented, it cannot be speculated how such pain behaves in a longer time frame and how many patients would require conversion to total ankle

This article is a preprint. It has been reviewed, accepted for publication, and approved by the author but has not been copyedited, proofread, or typeset.

arthroplasty or fusion. We found only one other published study with short-term results, by Lerch et al. [3]. In contrast to our results, they reported an increase in the AOFAS (American Orthopedic Foot and Ankle Society) score from 55.5 to 79.5 points and the EFAS (European Foot and Ankle Society) score from 5.6 to 13.5 points, pre- to postoperative. An improvement in the pain score according to the VAS scale from 3 to 1.1 points was also noted. However, they only presented short-term data with a follow-up of only 3 months, thus making it difficult to compare with our study. HemiCap[®] has been available on the market for a little more than a decade, and therefore short-term results with relatively small patient numbers have already been presented. Our data concur with the positive results of van Bergen et al. and Vuurberg et al. [11–13]. Talus hemiarthroplasty is infrequently used because it is considered a last option for complex OLT treatment, when arthroscopic or open biologic osteochondral repair is no longer feasible. Looking at our own statistics, as a tertiary referral center for cartilage repair, only six HemiCap[®] treatments were performed out of 150 OLT procedures over 7 years [27].

This study must be interpreted in light of the following limitations. The sample size was small and the two groups presented were heterogenous. It was a non-randomized and unblinded case series. On the other hand, we presented a real clinical situation: a data registry of the entire patient series treated with these two innovative methods. Due to the organization of orthopedic healthcare in a small country, patients tend to gravitate back to their primary surgeons for follow-up visits, in the case of an adverse event, or for subsequent revisions. Furthermore, there is the possibility of a subjective bias in treatment decisions and radiographic

This article is a preprint. It has been reviewed, accepted for publication, and approved by the author but has not been copyedited, proofread, or typeset.

imaging analyses. Attention was paid to standardizing the inclusion and digital measurement protocols, and so we are confident that variability was reduced to a minimum. Moreover, the outcome was only assessed with standard ankle-specific and general quality-of-life outcome questionnaires. Systemic diseases, conjoined foot pathology, and the low number of cases may also represent a certain bias for the patient-reported evaluation in this study.

Conclusions

Based on a small and heterogeneous prospective case series—talar dome resurfacing for symmetrical, mild-to-moderate ankle OA and talus hemiarthroplasty for chronic, large, deep, or recurrent OLTs—were safe and stable over a 2-year follow-up period, without any radiographic OA progression of the remaining joint. However, patient-reported ankle function, quality of life, and activity level showed a tendency of only minor improvement after resurfacing, but a moderate increase after hemiarthroplasty. Additional clinical data from other authors are required, before a wider usage of these two innovative talus resurfacing implants is promoted.

Financial Disclosure: The study was funded by the University Medical Centre Ljubljana - Institutional research funding grant #20190041 to Matej Drobnič.

Conflict of Interest: Matej Drobnič is a clinical consultant for Arthrex GmbH, Germany.

This article is a preprint. It has been reviewed, accepted for publication, and approved by the author but has not been copyedited, proofread, or typeset.

References

1. Ebskov LB, Andersen KH, Rasmussen PB, Johansen JK, Benyahia M. Mid-term results after treatment of complex talus osteochondral defects with HemiCAP implantation. *Foot Ankle Surg* 2020;26(4):384–90. <https://doi.org/10.1016/j.fas.2019.05.003>
2. Bloch B, Srinivasan S, Mangwani J. Current concepts in the management of ankle osteoarthritis: a systematic review. *J Foot Ankle Surg* 2015;54(5):932–9. <https://doi.org/10.1053/j.jfas.2014.12.042>
3. Lerch M, Yao D, Ettinger S, Claassen L, Plaass C, Stukenborg-Colsman C. The Ankle Spacer—a hemiarthroplasty for treatment of severe osteochondral defects of the talus. *Oper Orthop Traumatol* 2021 Aug 25. Available from: <https://doi.org/10.1007/s00064-021-00719-6>. Epub ahead of print.
4. Looze CA, Capo J, Ryan MK, Begly JP, Chapman C, Swanson D, et al. Evaluation and management of osteochondral lesions of the talus. *Cartilage* 2017;8(1):19–30. <https://doi.org/10.1177/1947603516670708>
5. Heijink A, Gomoll AH, Madry H, Drobnič M, Filardo G, Espregueira-Mendes J, et al. Biomechanical considerations in the pathogenesis of osteoarthritis of the knee. *Knee Surg Sports Traumatol Arthrosc* 2012;20(3):423–35. <https://doi.org/10.1007/s00167-011-1818-0>
6. Zengerink M, Struijs PA, Tol JL, Van Dijk CN. Treatment of osteochondral lesions of the talus: a systematic review. *Knee Surg Sports Traumatol Arthrosc* 2010;18(2):238–46. <https://doi.org/10.1007/s00167-009-0942-6>

This article is a preprint. It has been reviewed, accepted for publication, and approved by the author but has not been copyedited, proofread, or typeset.

7. Marcacci M, Filardo G, Kon E. Treatment of cartilage lesions: what works and why? *Injury* 2013;44(Suppl. 1):S11–5. [https://doi.org/10.1016/S0020-1383\(13\)70004-4](https://doi.org/10.1016/S0020-1383(13)70004-4)
8. Murawski CD, Kennedy JG. Operative treatment of osteochondral lesions of the talus. *J Bone Joint Surg Am* 2013;95(11):1045–54. <https://doi.org/10.2106/JBJS.L.00773>
9. van Bergen CJ, Zengerink M, Blankevoort L, van Sterkenburg MN, van Oldenrijk J, van Dijk CN. Novel metallic implantation technique for osteochondral defects of the medial talar dome: a cadaver study. *Acta Orthop* 2010;81(4):495–502.
<https://doi.org/10.3109/17453674.2010.492764>
10. Anderson DD, Tochigi Y, Rudert MJ, Vaseenon T, Brown TD, Amendola A. Effect of implantation accuracy on ankle contact mechanics with a metallic focal resurfacing implant. *J Bone Joint Surg Am* 2010;92(6):1490–500. <https://doi.org/10.2106/JBJS.I.00431>
11. van Bergen CJ, Reilingh ML, van Dijk CN. Novel metal implantation technique for secondary osteochondral defects of the medial talar dome: 1-year results of a prospective study. *Fuss Sprunggelenk* 2012;10:130–7. <https://doi.org/10.1016/j.fuspru.2012.03.004>
12. van Bergen CJ, van Eekeren IC, Reilingh ML, Sierevelt IN, van Dijk CN. Treatment of osteochondral defects of the talus with a metal resurfacing inlay implant after failed previous surgery: a prospective study. *Bone Joint J* 2013;95(12):1650–5.
<https://doi.org/10.1302/0301-620X.95B12.32455>
13. Vuurberg G, Reilingh ML, van Bergen CJ, van Eekeren IC, Gerards RM, van Dijk CN. Metal resurfacing inlay implant for osteochondral talar defects after failed previous surgery: a

This article is a preprint. It has been reviewed, accepted for publication, and approved by the author but has not been copyedited, proofread, or typeset.

midterm prospective follow-up study. *Am J Sports Med* 2018;46(7):1685–92.

<https://doi.org/10.1177/0363546518764916>

14. Kellgren JH, Lawrence JS. Radiological assessment of osteo-arthrosis. *Ann Rheum Dis* 1957;16(4):494–502. <http://dx.doi.org/10.1136/ard.16.4.494>

15. Hepple S, Winson IG, Glew D. Osteochondral lesions of the talus: a revised classification. *Foot Ankle Int* 1999;20(12):789–93. <https://doi.org/10.1177/107110079902001206>

16. Roos EM, Brandsson S, Karlsson J. Validation of the foot and ankle outcome score for ankle ligament reconstruction. *Foot Ankle Int* 2001;22(10):788–94.

<https://doi.org/10.1177/107110070102201004>

17. Rupel VP, Srakar A, Rand K. Valuation of EQ-5 D-3 I Health states in Slovenia: VAS based and TTO based value sets. *Zdr Varst* 2019;59(1):8–17. <https://doi.org/10.2478/sjph-2020-0002>

18. Martin RL, Irrgang JJ, Burdett RG, Conti SF, Swearingen JMV. Evidence of validity for the Foot and Ankle Ability Measure (FAAM). *Foot Ankle Int* 2005;26(11):968–83.

<https://doi.org/10.1177/107110070502601113>

19. Tegner Y, Lysholm J. Rating systems in the evaluation of knee ligament injuries. *Clin Orthop Relat Res* 1985;198:43–9. <https://doi.org/10.1097/00003086-198509000-00007>

20. Kolar M, Brulc U, Stražar K, Drobnič M. Patient-reported joint status and quality of life in sports-related ankle disorders and osteoarthritis. *Int Orthop* 2021;45(4):1049–55.

<https://doi.org/10.1007/s00264-020-04747-y>

This article is a preprint. It has been reviewed, accepted for publication, and approved by the author but has not been copyedited, proofread, or typeset.

21. Kon E, Robinson D, Verdonk P, Drobnic M, Patrascu JM, Dulic O, et al. A novel aragonite-based scaffold for osteochondral regeneration: early experience on human implants and technical developments. *Injury* 2016;47:S27–S32. [https://doi.org/10.1016/S0020-1383\(16\)30836-1](https://doi.org/10.1016/S0020-1383(16)30836-1)
22. Feucht MJ, Cotic M, Beitzel K, Baldini JF, Meidinger G, Schöttle PB, et al. A matched-pair comparison of inlay and onlay trochlear designs for patellofemoral arthroplasty: no differences in clinical outcome but less progression of osteoarthritis with inlay designs. *Knee Surg Sports Traumatol Arthrosc* 2017;25(9):2784–91. <https://doi.org/10.1007/s00167-015-3733-2>
23. Robertson GA, Wood AM. Hip hemi-arthroplasty for neck of femur fracture: what is the current evidence? *World J Orthop* 2018;9(11):235–44. <https://doi.org/10.5312/wjo.v9.i11.235>
24. Antuña SA, Sperling JW, Cofield RH. Shoulder hemiarthroplasty for acute fractures of the proximal humerus: a minimum five-year follow-up. *J Shoulder Elbow Surg* 2008;17(2):202–9. <https://doi.org/10.1016/j.jse.2007.06.025>
25. Schmitz PP, van Susante JLC, Somford MP. Low conversion rates toward total hip arthroplasty after hemiarthroplasty in patients under 75 years of age. *Eur J Orthop Surg Traumatol* 2019;29(8):1687–91. <https://doi.org/10.1007/s00590-019-02498-0>

This article is a preprint. It has been reviewed, accepted for publication, and approved by the author but has not been copyedited, proofread, or typeset.

26. Ferrel JR, Trinh TQ, Fischer RA. Reverse total shoulder arthroplasty versus hemiarthroplasty for proximal humeral fractures: a systematic review. *J Orthop Trauma* 2015;29(1):60–8.
<https://doi.org/10.1097/BOT.0000000000000224>
27. Brulc U, Drobnič M, Kolar M, Stražar K. A prospective, single-center study following operative treatment for osteochondral lesions of the talus. *Foot Ankle Surg* 2021 Aug 26.
Available from: <https://doi.org/10.1016/j.fas.2021.08.008>. Epub ahead of print.

This article is a preprint. It has been reviewed, accepted for publication, and approved by the author but has not been copyedited, proofread, or typeset.

Table 1. Demographic data and surgical details.

Variable	Resurfacing (<i>n</i> = 11)	Hemiarthroplasty (<i>n</i> = 6)
Age (years)	54 (<i>SD</i> = 14)	54 (<i>SD</i> = 7)
Sex (female/male)	7/4	2/4
BMI (kg/m ²)	27.4 (<i>SD</i> = 5.6)	30.2 (<i>SD</i> = 3.5)
Main diagnosis, <i>n</i>	Post-traumatic OA, 7 Post-OLT OA, 2 Psoriatic arthritis, 1 Hemophilic arthropathy, 1	Post-traumatic OLT, 4 Non-traumatic OLT, 2
Concomitant surgery, <i>n</i>	None, 4 Osteophyte removal, 2 Gastroc/Achilles lengthening, 3 Supra/infra-malleolar osteotomy, 2	None, 4 Subtalar fusion, 1 Arthroeresis, 1

BMI = body mass index, OA = osteoarthritis, OLT = osteochondral lesions of the talus

This article is a preprint. It has been reviewed, accepted for publication, and approved by the author but has not been copyedited, proofread, or typeset.

Table 2. Clinical outcomes and the radiographic evaluation of partial ankle arthroplasty

subjects.

Measure	Talus resurfacing (<i>n</i> = 11)			Talus hemiarthroplasty (<i>n</i> = 6)		
	Preop	Postop	<i>p</i> -value	Preop	Postop	<i>p</i> -value
Active dorsiflexion, ° (<i>SD</i>)	3 (4)	10 (9)	0.034	15 (6)	22 (4)	0.025
Active plantarflexion, ° (<i>SD</i>)	29 (8)	21 (13)	0.171	29 (9)	38 (4)	0.067
FAOS						
Symptoms (<i>SD</i>)	47 (21)	47 (29)	0.983	59 (34)	66 (33)	0.731
Pain (<i>SD</i>)	45 (17)	48 (25)	0.646	61 (24)	70 (25)	0.541
ADL (<i>SD</i>)	50 (21)	51 (25)	0.904	69 (24)	77 (24)	0.609
Sports (<i>SD</i>)	14 (15)	10 (15)	0.170	45 (29)	50 (34)	0.758
QoL (<i>SD</i>)	19 (19)	26 (26)	0.298	17 (13)	46 (37)	0.063
Cumulative (<i>SD</i>)	41 (16)	42 (32)	0.747	58 (23)	68 (28)	0.536
FAAM-ADL (<i>SD</i>)	43 (12)	46 (22)	0.591	37 (15)	71 (26)	0.004
EQ-5D 3L TTO (<i>SD</i>)	0.38 (0.17)	0.39 (0.17)	0.865	0.53 (0.15)	0.72 (0.22)	0.129

This article is a preprint. It has been reviewed, accepted for publication, and approved by the author but has not been copyedited, proofread, or typeset.

Tegner activity scale (SD)	1.6 (1.4)	2.0 (1.5)	0.476	3.1 (2.1)	3.1 (1.5)	0.793
KL OA grade (0/I/II/III/IV)	0/0/3/8/0	0/0/3/8/0	n. a.	0/1/4/1/0	0/1/4/1/0	n. a.
Peri-implant radiography						
No changes	–	11	n. a.	–	6	n. a.
Revision surgeries						
None	–	10	n. a.	–	4	n. a.
Not implant related	–	1	n. a.	–	2	n. a.

OP = operative, FAOS = Foot and Ankle Outcome Score, EQ-5D 3L TTO = European quality of life in five dimensions three-level time trade-off values, KL OA grade = ankle AP radiographs evaluated according to Kellgren–Lawrence osteoarthritis criteria, FAAM-ADL = Foot and Ankle Ability Measures for daily activities; statistical significance was set at $p < .05$.

This article is a preprint. It has been reviewed, accepted for publication, and approved by the author but has not been copyedited, proofread, or typeset.

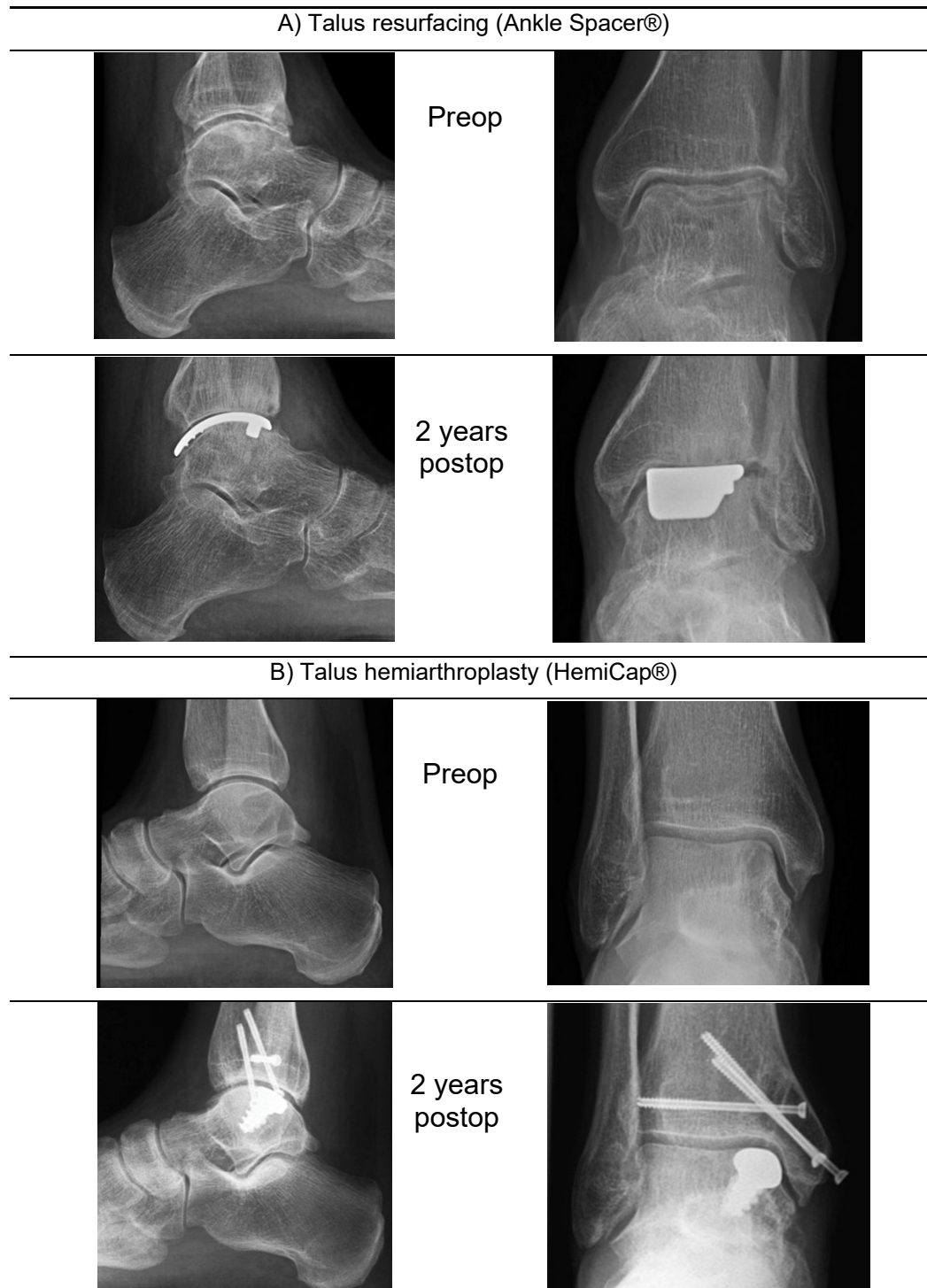


Figure 1. Representative preoperative and 2-year weight-bearing radiographs of A) talus resurfacing (41-year-old male subject with hemophilic arthropathy), and B) talus hemiarthroplasty (55-year-old male subject with a chronic medial post-traumatic OLT).